

## A PROSPECTIVE COMPARISON OF FOUR METHODS OF ENDOVENOUS THERMAL ABLATION

ŁUKASZ DZIECIUCHOWICZ<sup>1</sup>, ZBIGNIEW KRASIŃSKI<sup>1</sup>, MARCIN GABRIEL<sup>1</sup>,  
GAUDENCIO ESPINOSA<sup>2</sup>

Department of General and Vascular Surgery, Medical University in Poznań<sup>1</sup>

Kierownik: prof. dr. hab. G. Oszkinis

Angiology and Vascular Surgery, University Hospital, University of Navarra, Pampeluna, Spain<sup>2</sup>

Kierownik: dr G. Espinosa

**The aim of the study** was to compare clinical and duplex Doppler results of treatment of varicose veins with four methods of endovenous thermal ablation (EVTA).

**Material and methods.** The results of treatment of varicose veins with 980 nm laser (EVLA980) in 67 extremities, with a radiofrequency ablation (RFA) in 43 extremities, with 810 nm laser (EVLA810) in 46 extremities and with 1470 nm laser (EVLA1470) in 15 extremities were prospectively analyzed. The data on patients' demographics, weight, stage of the venous disease, type of anesthesia, duration of the procedure, linear energy density (LED) applied, intra- and postoperative complications were collected. Thromboprophylaxis was not routinely administered. The patients were followed clinically and with duplex Doppler for 12 (1-24) months.

**Results.** Technical success was achieved in 99% of limbs. The procedure was carried out under local anesthesia in 140 (91%) of patients. In 17 patients bilateral procedure was performed. There were one gastrocnemius muscle vein thrombosis and one protruding thrombus from sapheno-femoral junction in EVLA810. No other serious complications were observed. A median LED was higher in EVLA810 than in EVLA980 and EVLA1470, 86.8 (82-94), 59.2 (45.4-74.4) and 58.8 (53-67.7) J/cm, respectively ( $p < 0.001$ ), though only in EVLA980 was below the intended range. Recanalization rates were 7% after EVLA980, 2% after EVLA810 and 0% after RFA and EVLA1470,  $p = 0.14$ . The vein shrinking was fastest after EVLA1470. Neither neovascularization nor formation of arteriovenous fistulas was observed. Permanent saphenous nerve paresthesia occurred in two patients after RFA.

**Conclusions.** All methods of ambulatory EVTA are safe and effective once the adequate linear energy density is applied.

**Key words:** varicose veins, thermal ablation, results

Varicose veins (VV) are an important social and health problem. In developed countries they occur in 25-50% of women and in 7-40% of men and their prevalence increases with age (1-4). Because of aging of the human population, it can be assumed that their prevalence will grow. VV may lead to phlebitis, bleeding and ulcers. Healing of venous leg ulcers is very long and expensive, they tend to reoccur and recurrent ulcers are more difficult to heal (5-8).

A standard surgical treatment of VV may be complicated by prolonged postoperative

pain, saphenous nerve injury, hematomas, wound infection and lymphatic vessels injury and even, though rarely, by femoral vessels injury and venous thromboembolism (9-15). Moreover a high percentage of recurrence following saphenectomy has been reported reaching 20-50% (16, 17).

In an attempt to find a less invasive and more effective alternative to saphenectomy an endovenous thermal ablation (EVTA) either by laser or radiofrequency has been introduced (18, 19). The methods of EVTA have a different mode of action and the basic difference is in the

length of electromagnetic wave that they use. Quite recently a 1470 nm laser has been introduced whose energy is predominantly absorbed by the water and not, like in case of commonly used wavelengths from 810 to 980 nm, by hemoglobin. In a radiofrequency ablation with the ClosurePlus device the venous wall is heated by radiofrequency wave to 85-90°C. Recently a ClosureFAST device has been introduced which heats the venous wall to 120°C.

Thus the purpose of the study was to compare the results of treatment of VV with different methods of EVTA including the recently introduced systems.

## MATERIAL AND METHODS

After approval of local ethical committee results of treatment in four groups of patients were prospectively analyzed. The EVLA980 group consisted of 59 patients (67 limbs), in whom EVTA was performed with 980 nm laser (Cerelas D15, Biolitec). The RFA group consisted of 40 patients (43 limbs), in whom EVTA was performed with radiofrequency (RFA, Closure Fast, VNUS). The EVLA810 comprised 41 patients (46 limbs), in whom EVTA was performed with 810 nm laser (Varilase). The EVLA1470 consisted of 14 patients (15 limbs), in whom EVTA was performed with 1470 nm laser (Cerelas E, Biolitec). The patients from EVLA980 were treated in the years 2004-2006 and the remaining patients were treated in the years 2008-2009.

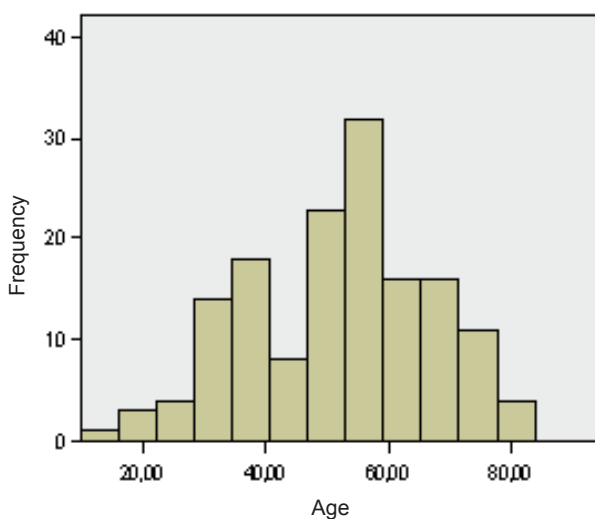


Fig. 1. Histogram presenting a distribution of age in 164 patients treated with endovenous thermal ablation

Altogether 161 limbs in 154 patients were treated. In 17 patients both limbs were treated during the same procedure. In 1 patient from EVLA980 group the procedure was abandoned because of failure to introduce a guide-wire into a postphlebotic great saphenous vein. In another patient from EVLA980 group the procedure was not performed because of laser generator failure. The mean age of patients was 52 (14.7) years and one fourth of patients was more than 60 years old (fig. 1). There were 109 (71%) of women. The mean body mass index (BMI) was 26.6 (4.5). In more than 25% of patients overweight was diagnosed (BMI>25) and another 25% presented obesity (BMI>30) (fig. 2).

Altogether 147 great saphenous veins (GSV), 23 small saphenous veins (SSV), 1 Giacomini vein, 8 anterior accessory saphenous veins (AASV) and 6 dilated thigh tributaries of GSV were treated. In 14 limbs more than one venous trunk was ablated. The distribution of treated veins did not differ between the groups,  $p=0.27$ .

The reflux in saphenous veins was classified according to Hach as follows: 2° in 24, 3° in 117 and 4° in 28 veins. There were no difference between the groups,  $p=0.46$ .

According to clinical part of CEAP classification chronic venous insufficiency was categorized as C2 in 143, C3 in 5, C4 in 12, C5 in 2

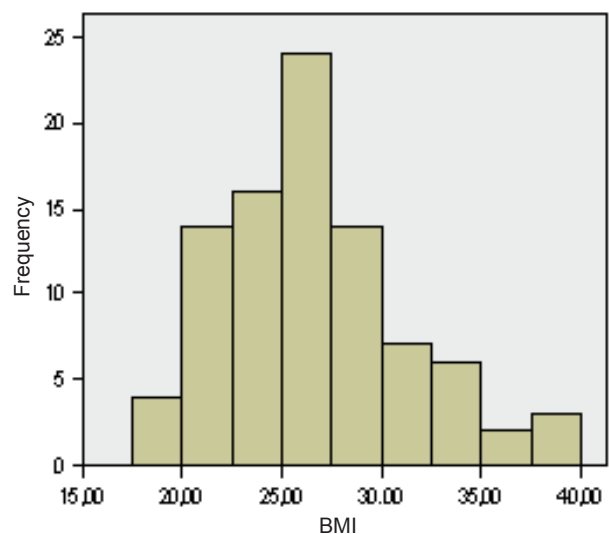


Fig. 2. Histogram presenting a distribution of body mass index (BMI) in 164 patients treated with endovenous thermal ablation

and C6 in 9 limbs. There were no difference between the groups,  $p=0.45$ .

The ablations were carried out according to standard techniques. According to the recommendation of the manufacturer, the aim was to deliver 40-80 J, 60-100 J and 40-60 J for 1 cm of treated vein in EVLA980, EVLA810 and EVLA1470 group, respectively. The antithrombotic prophylaxis was not routinely administered.

After the procedure its duration, number and length of ablated venous trunks, type of anesthesia, distance from the tip of the device to the sapheno-femoral (SFJ) or sapheno-popliteal (SPJ) junctions, linear energy density (LED) and total energy delivered in case of EVLA and number radiofrequency cycles in case of RFA were recorded. The data on the intra- and postoperative complications and duration of hospital postprocedural stay were also collected.

Clinical and duplex Doppler examinations, were performed before the procedure, 24 hours, 10 days, 3 and 6 months after the procedure and every 6 months thereafter. The results of ablation were categorized according to modified classification of Merchant et al. (fig. 3) (20). The diameter of saphenous veins 3 cm from SFJ or SPJ was also measured.

The follow-up period averaged 12 (1-24) months. The mean follow-up period in RFA and EVLA1470 groups was shorter than in EVLA980 and EVLA810 groups, 6 and 7 months and 15 and 12 months respectively,  $p<0.001$ .

A statistical analysis was performed with SPSS for Windows version 15.0. Quantitative variables with normal distribution were described with mean and standard deviation and compared with ANOVA test. Post hoc analysis with Student-Neuman-Keuls was done when

statistically significant differences occurred. Quantitative variables not normally distributed were described with median and interquartile range and compared with Kruskal-Wallis test. Nominal variables were compared with chi<sup>2</sup> test. Ordinal variables were compared with Kruskal-Wallis test. The differences were considered statistically significant with double tailed  $p<0.05$ .

## RESULTS

The mean length of ablated venous trunk was 47 (16) cm. The differences between the groups did not reach statistical significance,  $p=0.075$  (44.5 (14.3), 52.8 (17.7), 45.2 (15.8) and 46 (14.5) cm) for EVLA980, RFA, EVLA810 and EVLA1470, respectively. The mean diameter of saphenous veins was 7.4 (2.5) mm. There were no statistically significant differences between the groups,  $p=0.59$  (7.3 (2.7), 7.9 (2.5), 7.1 (2) and 6.7 (2) mm) for EVLA980, RFA, EVLA810 and EVLA1470, respectively. The distance from the tip of the device and SFJ or SPJ averaged 14.5 (4.7) mm and did not differ between the groups.

The procedure was carried out under local (tumescence) anesthesia in 140 (91%), under general anesthesia in 9 (6%) and under spinal anesthesia in 5 (3%) patients. In 148 (96%) patients miniphlebectomy was performed during the same procedure.

In case of EVLA, total energy for the limb, total energy for the patients and LED was significantly higher in EVLA810 group than in EVLA980 and EVLA1470 groups (tab. 1) though only in EVLA980 LED was below intended range. In RFA group mean number of radiofrequency cycles for the limb and for the patients was 9 (3.2) and 10 (3.6), respectively.

Mean duration of procedure was 98 (32.9) minutes and did not differ between the groups,  $p=0.65$ . Serious intraoperative complications did not occur. In one patient from EVLA980 group a transient confusion during application of tumescence anesthesia was noted and was attributed to intravascular injection of lidocaine.

Mean postoperative stay in recovery area was 200 (60) minutes and did not differ between the groups,  $p=0.97$ .

There were no serious complications postoperatively. In one patient after ablation of SSV with 810 nm laser a symptomatic throm-

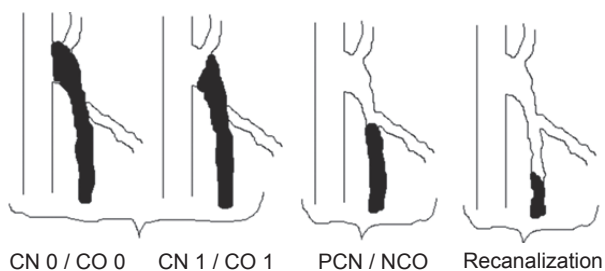


Fig. 3. Classification of vein occlusion according to Merchant et al. 20 CO – complete occlusion, NCO – near complete occlusion

Table 1. Linear energy density (LED), energy per limb and total energy delivered in groups of patients treated with endovenous laser ablation. The values are expressed as median and interquartile range

Group	EVLA 980 nm	EVLA 810 nm	EVLA 1470 nm	p
LED (J/cm)	59,2 (45,4-74,4)	86,8 (82-94)	58,8 (53-67,7)	<0,001
Energy per limb (J)	2125 (1628-2892)	4265 (3236-4910)	3319 (1840-3635)	<0,001
Total energy (J)	2197 (1670-3200)	4584 (3838-5496)	3407 (1708-4547)	<0,001

basis of gastrocnemius vein draining into SSV was found though during the procedure fibre tip was positioned below the junction of these veins. In another patient from EVLA810 group a protruding thrombus from SFJ to common femoral vein was observed. Thus an overall incidence of deep venous thrombosis was 1.3% (2/154) and increased to 4.9% (2/41) when only 810 nm laser was considered. Twelve patients reported saphenous nerve paresthesia on the 10th postoperative day. They were more frequent after RFA than after EVLA980, EVLA810 and EVLA1470, 13.9 (6/43)%, 3 (2/67)% i 4.5 (2/46)% i 0 (0/15)%, respectively (p=0.064). Because of severity of symptoms, one RFA patient required pharmacological treatment. After three months, paresthesia disappeared in all but 2 patients from RFA group.

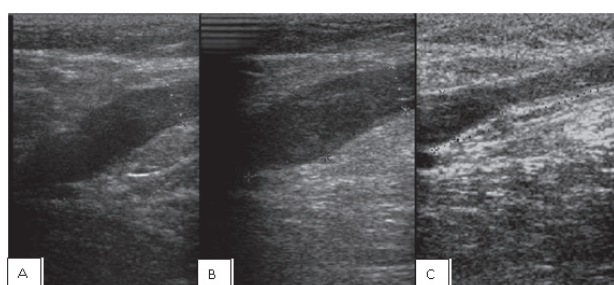


Fig. 4. Changes of a diameter of proximal segment of GSV after ablation with 980nm laser. The diameter measured 3 cm from sapheno-femoral junction is marked with green colour and is 8.8 mm, 8.5 mm and 4.5 mm before the procedure (A), 10 days after the procedure (B) and 3 months after the procedure (C), respectively

Six GSVs recanalized in EVLA980 within the first six months. Four of them occurred in the first 20 patients in whom LED was below the aimed range. Another early recanalisation was attributed to the presence of grossly dilated and refluxing superficial epigastric vein. There was one recanalisation in EVLA810 group. No recanalisations were observed in RFA and EVLA1470 groups. The data on vein occlusion is presented in tab. 2.

In duplex Doppler a reduction in diameter of ablated veins was observed in all groups (fig. 4 and 5). The shrinking of the veins was fastest in EVLA1470 group (tab. 3). There were no cases of arterio-venous fistula in the vicinity of ablated veins. What was seen however was the presence of arterial vessels adjacent to GSV in the groin that was confirmed by triphasic, high resistance flow pattern and resistance index >0.8 (fig. 6).

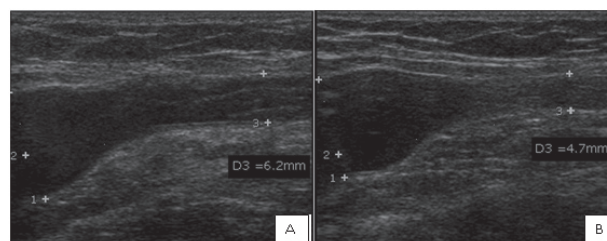


Fig. 5. Changes of a diameter of proximal segment of GSV after ablation with ClosureFAST RFA. The diameter measured 3 cm from sapheno-femoral junction is marked D3 and is 6.2 mm and 4.7 mm after 10 days (A) and 6 months (B), respectively

Table 2. Occlusion status of ablated veins

	EVLA980 nm n (%)	RAF ClosureFAST n (%)	EVLA810 nm n (%)	EVLA1470 nm n (%)
Complete occlusion	56 (84)	39 (91)	39 (85)	15 (100)
Near complete occlusion	6 (9)	4 (9)	6 (13)	0
Recanalization	5 (7)	0	1 (2)	0



Table 3. Percentage of diameter reduction after four methods of endovenous thermal ablation

	10 days	6 months
RFA	24%	51%
EVLA980 nm	10%	46%
EVLA810 nm	15%	50%
EVLA1470 nm	42%	80%

## DISCUSSION

This study confirmed that ambulatory EVTA is an effective and safe method of treatment of VV even in patients with risk factors such as obesity, age above 60 and advanced chronic venous insufficiency (21, 22). There were no any major complications. Although in majority of patients antithrombotic prophylaxis was not used the incidence of DVT was only 1.3% that is much less than 5% reported after VV surgery (23). Moreover these were only distal DVT in one case and protruding thrombus from the SFJ in another. The reported incidence of DVT in the literature, which is most often a protruding thrombus from SFJ, varies from 16% to 0.9% after ClosurePlus RFA (24, 25, 26) and from 7.9% to 0% after EVLA (27-33). The possibility of prothrombotic activation of haemostasis by radiofrequency has been discarded in patient undergoing ablation procedure in the heart (34, 35).

The higher incidence of DVT after treatment with ClosurePlus RFA could be related to the slow retraction rate, 1cm/min that causes a prolonged exposure of the SFJ region to high temperature (24). Puggioni et al. reported a lower incidence of thrombotic events with increasing the speed of retraction, 20% and 9.7% respectively ( $p=0.02$ ) (26). It is also possible that the working tip of the ClosurePlus catheter is more thrombogenic than a tip of an optic fibre or ClosureFAST. In a multi-centre study of RFA ClosureFAST in 295 limbs, thrombo-embolic complications were not observed (36). Both observed thrombotic incidents in our study as well as majority of thrombotic complications reported in the literature occurred after EVLA with 810 nm laser. Laser 810 nm, like 940 nm and 980 nm lasers, uses axial optic fibre, but its energy is absorbed by hemoglobin in a greater degree than with other wavelengths. That is why 810 nm can be more prone to induce heat

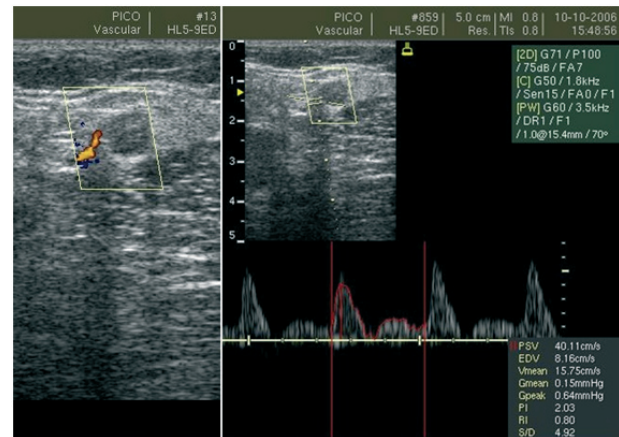


Fig. 6. Duplex scan showing the occluded GSV after laser ablation with an adjacent arterial vessels (resistance index 0.8). The arterio-venous fistula was not seen

thrombosis ahead of the fibre. A 1470 nm laser due to radial emission of energy and the fact that its energy is predominately absorbed by the water of the venous wall and not by hemoglobin should carry the lowest risk of heat induced thrombosis. As a matter of fact we did not observe any thrombotic events after EVLA with 1470 nm laser but the small number of patients does not allow drawing definite conclusions. Also Pannier et al. did not observe any DVT after EVLA with 1470 nm laser in 111 limbs but they used perioperative antithrombotic prophylaxis (37). Another issue is the fact that in our study as well as in the studies reporting low incidence of periprocedural DVT almost all the patients were operated under local anesthesia (28, 29, 36, 38). The general or spinal anesthesia by prolonging the immobilization of the patient may increase the risk of thromboembolic complications (24, 30, 31).

Another important finding of this study is that all examined methods of EVTA seem to be equally effective once the adequate amount of energy is delivered. In the study the highest, though not statistically significant, recurrence rate, in EVLA980 group was observed. This was the only group, that probably because of learning curve effect, LED was bellowed. Similarly Theivacumar et al. suggested that  $LED > 60$  J/cm guarantees 100% efficacy (39). It seems that with 1470 nm laser good clinical results can be obtained with smaller amount of energy what can lead to smaller incidence of complications, mainly paresthesia.

Although it has been postulated, that in distinction to laser ablation, vein contraction is a main component of action of RFA, in this study no differences were observed between rate of diameter reduction of ablated veins between lasers 810 nm and 980 nm and radiofrequency. Similarly Creton et al. in a recently published study found only 20% reduction of diameter of GSV 3 days after RFA with ClosureFAST (36). It seems that both in case of RFA and lasers 810-980 nm venous thrombosis with intimal injury that hinders subsequent recanalisation are the main mechanism of action. On the other hand the 1470 nm laser seems to have a different mechanism of action related not only to thrombosis and intimal injury but also to permanent contraction of ablated vein. Despite delivering significantly lower LED than in case of 810 nm and 980 nm laser, laser 1470 nm causes faster shrinking of the vein what can influence the long-term results. These potential advantages results probably from radial laser beam emission and direct, and not as in case of lasers 810 nm and 980 nm indirect, action on the venous wall.

Avoidance of groin dissection and SFJ disconnection that may lead to neovascularisation and varicose veins recurrence is a potential advantage of EVTA (16, 17, 40). In this study, as well as in the studies of other authors, a SFJ or SPJ neovascularization was not observed and its occurrence seems very unlikely (41, 42). The only neovascularization that was reported after EVTA was observed in patients who had also crosssection performed (43). First of all heat ablation process if adequately performed is endoluminal with little or no perivenous inflammatory reaction. Second of all, as it was observed in this study, in majority of cases the saphenous bulb remains patent to the junction of superficial epigastric vein and acts as a safety valve for the venous hypertension (41, 44). Labropoulos et al. reported in 5 (5%) of 102 patients as early as in a week after RFA or EVLA neovascularisation within the saphenous vein thrombus and stated that it was caused by development of arterio-venous fistulas (45). In the present study the arteriovenous fistulas were not detected. Similarly Ravi et al. analyzing 3000 cases of EVLA did not observed arteriovenous fistulas (38). With regard to the study of Labropoulos et al. we believe that it is too soon

to speak about neovascularisation as early as in a week after the procedure (45). Like others, we believe that development of arteriovenous fistula in an early postoperative period, which had been observed in 0.2% of patients, is only possible when there is a perforation of the ablated vein into the adjacent artery caused by the local overdose of energy (46, 47). It seems that absence of neovascularisation is especially important in case of SSV incompetency where the recurrence following stripping is as high as 30-52% (17, 48).

In 13 patients in this study, together with ablation of saphenous vein, other venous trunks, mainly anterior accessory saphenous vein, were also obliterated. Leaving behind fragments of incompetent saphenous or other superficial venous trunks is another, beside neovascularisation, cause of VV recurrence (49). We believe that the use of intraoperative duplex Doppler is another advantage of EVTA. This eliminates the risk of leaving behind any incompetent part of saphenous trunk, for example in case of its total or what is more frequent partial duplication, and overlooking other incompetent venous trunks.

In this study saphenous nerve paresthesia were more frequent after ClosureFAST RFA though the extent of GSV ablation was the same in all groups. This finding is consistent with the previous reports concerning ClosurePlus RFA. Merchant and Pichot reported saphenous nerve paresthesia in 13.3% of patients a week after below knee RFA. In 7.7% the paresthesia were permanent (25). In other prospective, randomized studies the incidence of paresthesia after RFA was not lower than after saphenectomy (50, 51). In a recently published multicentre study saphenous nerve paresthesia were observed in 3.4% of limbs after ClosureFAST RFA (36). The incidence of paresthesia following EVLA is lower ranging 0-7% of which less than 1% is permanent (28, 29, 33, 52). With EVLA the operator can decrease LED in the crural part of GSV either by reducing the power or accelerating the retraction of the fibre. Moreover in an experimental study it has been shown that in case of EVLA even without tumescent anesthesia the temperature outside the vein do not exceed 50°C (53). In case of RFA ClosurePlus though the speed of retraction can be controlled the aim is to heat the venous wall to 85-90°C. In case of RFA ClosureFAST the speed cannot be

controlled and temperature is even higher reaching 120°C.

The temperatures 85-120°C may be high enough to permanently injure adjacent to GSV saphenous nerve. That is why it seems very important, especially in case of RFA, to apply adequate tumescent anesthesia to protect the saphenous nerve from thermal injury. In a recently published study analyzing 127 EVLAs with 1470 nm laser postoperative saphenous nerve or sural nerve paresthesia occurred in as many as 9.5% of patients and in 7.6% they were permanent (37). Contrary to the aforementioned report we did not observe any paresthesia after EVLA with 1470 nm laser. This difference can be explained by the fact that the authors of the cited article applied twice as high LED averaging 107 J/cm in case of GSV and 129 J/cm in case of SSV. They also found that higher LED is related to higher incidence of paresthesia, 15.5% and 2.3% for

LED > 100 J/cm (mean 123 J/cm) and <100 J/cm (mean 88 J/cm), respectively (p=0.04). Since in case of 1470 nm laser LED of 60 J/cm is sufficient for permanent saphenous vein obliteration it can be concluded that this type of ablation carries very low risk of postoperative paresthesia.

## CONCLUSIONS

Ambulatory EVTA is an effective and safe method of treatment of superficial venous trunks insufficiency even in patients with thrombotic risk factors. All the examined methods seem to be equally effective once adequate LED is applied. RFA has a higher risk of postoperative paresthesia than EVLA. The advantage of 1470 nm laser is high efficacy with low LED and fast vein contraction which may yield better long-term results and fewer perioperative complications.

## REFERENCES

1. Carpentier PH, Maricq HR, Biro C et al.: Prevalence, risk factors and clinical patterns of chronic venous disorders of lower limbs: a population-based study in France. *J Vasc Surg* 2004; 40(4): 650-59.
2. Sisto T, Reunanen A, Laurikka J et al.: Prevalence and risk factors of varicose veins in lower extremities: mini-Finland health survey. *Eur J Surg* 1995; 161(6): 405-14.
3. Evans CJ, Fowkes FG, Ruckley CV et al.: Prevalence of varicose veins and chronic venous insufficiency in men and women in the general population: Edinburgh Vein Study. *J Epidemiol Community Health* 1999; 53(3): 149-53.
4. Jawien A, Grzela T, Ochwat A: Prevalence of chronic venous insufficiency in men and women in Poland: multicentre cross-sectional study in 40,095 patients. *Phlebology* 2003; 18: 110-22.
5. Nelzén O, Bergqvist D, Lindhagen A: Venous and non-venous leg ulcers: clinical history and appearance in a population study. *Br J Surg* 1994; 81(2): 182-87.
6. Wright DD, Franks PJ, Blair SD et al.: Oxerutins in the prevention of recurrence in chronic venous ulceration: randomized controlled trial. *Br J Surg* 1991; 78(10): 1269-70.
7. Ragnarson Tennvall G, Hjelmgren J: Annual costs of treatment for venous leg ulcers in Sweden and the United Kingdom. *Wound Repair Regen* 2005; 13(1): 13-18.
8. Jantet G: Impact socio-économique de la pathologie veineuse en Grande Bretagne. *Phlébologie* 1992; 45: 433-37.
9. Subramonia S, Lees T: Sensory abnormalities and bruising after long saphenous vein stripping: impact on short-term quality of life. *J Vasc Surg* 2005; 42(3): 510-14.
10. Wood JJ, Chant H, Laugharne M et al.: A prospective study of cutaneous nerve injury following long saphenous vein surgery. *Eur J Vasc Endovasc Surg* 2005; 30(6): 654-58.
11. Morrison C, Dalsing MC: Signs and symptoms of saphenous nerve injury after greater saphenous vein stripping: prevalence, severity, and relevance for modern practice. *J Vasc Surg* 2003; 38(5): 886-90.
12. Davies AH, Steffen C, Cosgrove C et al.: Varicose vein surgery: patient satisfaction. *J R Coll Surg Edinb* 1995; 40(5): 298-99.
13. Mackay DC, Summerton DJ, Walker AJ: The early morbidity of varicose vein surgery. *J R Nav Med Serv* 1995; 81(1): 42-46.
14. Critchley G, Handa A, Maw A et al.: Complications of varicose vein surgery. *Ann R Coll Surg Engl* 1997; 79(2): 105-10.
15. Miller GV, Lewis WG, Sainsbury JR et al.: Morbidity of varicose vein surgery: auditing the benefit of changing clinical practice. *Ann R Coll Surg Engl* 1996; 78(4): 345-49.
16. Kostas T, Ioannou CV, Touloupakis E et al.: Recurrent varicose veins after surgery: a new appraisal of a common and complex problem in vascular surgery. *Eur J Vasc Endovasc Surg* 2004; 27(3): 275-82.
17. van Rij AM, Jiang P, Solomon C et al.: Recurrence after varicose vein surgery: a prospective long-term clinical study with duplex ultrasound scanning and air plethysmography. *J Vasc Surg* 2003; 38(5): 935-43.



18. Boné C: Tratamiento endoluminal de las várices con láser de diodo: estudio preliminar. *Rev Patol Vasc* 1999; 5: 35-68.
19. Chandler JG, Pichot O, Sessa C et al.: Defining the role of extended saphenofemoral junction ligation: a prospective comparative study. *J Vasc Surg* 2000; 32(5): 941-53.
20. Merchant RF, DePalma RG, Kabnick LS: Endovascular obliteration of saphenous reflux: a multicenter study. *J Vasc Surg* 2002; 35(6): 1190-96.
21. Darvall KA, Sam RC, Adam DJ et al.: Higher prevalence of thrombophilia in patients with varicose veins and venous ulcers than controls. *J Vasc Surg* 2009; 49(5): 1235-41.
22. Mackenzie RK, Ludlam CA, Ruckley CV et al.: The prevalence of thrombophilia in patients with chronic venous leg ulceration. *J Vasc Surg* 2002; 35(4): 718-22.
23. van Rij AM, Chai J, Hill GB et al.: Incidence of deep vein thrombosis after varicose vein surgery. *Br J Surg* 2004; 91(12): 1582-85.
24. Hingorani AP, Ascher E, Markevich N et al.: Deep venous thrombosis after radiofrequency ablation of greater saphenous vein: a word of caution. *J Vasc Surg* 2004; 40(3): 500-04.
25. Merchant RF, Pichot O; Closure Study Group: Long-term outcomes of endovenous radiofrequency obliteration of saphenous reflux as a treatment for superficial venous insufficiency. *J Vasc Surg* 2005; 42(3): 502-09.
26. Puggioni A, Marks N, Hingorani A et al.: The safety of radiofrequency ablation of the great saphenous vein in patients with previous venous thrombosis. *J Vasc Surg* 2009 May; 49(5): 1248-55.
27. Agus GB, Mancini S, Magi G; IEWG: The first 1000 cases of Italian Endovenous-laser Working Group (IEWG). Rationale, and long-term outcomes for the 1999-2003 period. *Int Angiol* 2006; 25(2): 209-15.
28. Min RJ, Khilnani N, Zimmet SE: Endovenous laser treatment of saphenous vein reflux: long-term results. *J Vasc Interv Radiol* 2003; 14(8): 991-96.
29. Sharif MA, Soong CV, Lau LL et al.: Endovenous laser treatment for long saphenous vein incompetence. *Br J Surg* 2006; 93(7): 831-35.
30. Mozes G, Kalra M, Carmo M et al.: Extension of saphenous thrombus into the femoral vein: a potential complication of new endovenous ablation techniques. *J Vasc Surg* 2005; 41(1): 130-35.
31. Knipp BS, Blackburn SA, Bloom JR et al.: Michigan Venous Study Group. Endovenous laser ablation: venous outcomes and thrombotic complications are independent of the presence of deep venous insufficiency. *J Vasc Surg* 2008; 48(6): 1538-45.
32. Puggioni A, Kalra M, Carmo M et al.: Endovenous laser therapy and radiofrequency ablation of the great saphenous vein: analysis of early efficacy and complications. *J Vasc Surg* 2005; 42(3): 488-93.
33. Desmyttere J, Grand C, Wassmer B et al.: Endovenous 980-nm laser treatment of saphenous veins in a series of 500 patients. *J Vasc Surg* 2007; 46(6): 1242-47.
34. Lee DS, Dorian P, Downar E et al.: Thrombogenicity of radiofrequency ablation procedures: what factors influence thrombin generation? *Europace* 2001; 3(3): 195-200.
35. Dorbala S, Cohen AJ, Hutchinson LA et al.: Does radiofrequency ablation induce a prethrombotic state? Analysis of coagulation system activation and comparison to electrophysiologic study. *J Cardiovasc Electrophysiol* 1998; 9(11): 1152-60.
36. Creton D, Pichot O, Sessa C et al.: ClosureFast Europe Group. Radiofrequency-powered segmental thermal obliteration carried out with the ClosureFast procedure: results at 1 year. *Ann Vasc Surg* 2010; 24(3): 360-66.
37. Pannier F, Rabe E, Maurins U: First results with a new 1470-nm diode laser for endovenous ablation of incompetent saphenous veins. *Phlebology* 2009; 24(1): 26-30.
38. Ravi R, Trayler EA, Barrett DA et al.: Endovenous thermal ablation of superficial venous insufficiency of the lower extremity: single-center experience with 3000 limbs treated in a 7-year period. *J Endovasc Ther* 2009; 16(4): 500-05.
39. Theivacumar NS, Dellagrammaticas D, Beale RJ et al.: Factors influencing the effectiveness of endovenous laser ablation (EVLA) in the treatment of great saphenous vein reflux. *Eur J Vasc Endovasc Surg* 2008; 35(1): 119-23.
40. Nyamekye I, Shephard NA, Davies B et al.: Clinicopathological evidence that neovascularisation is a cause of recurrent varicose veins. *Eur J Vasc Endovasc Surg* 1998; 15(5): 412-15.
41. Pichot O, Kabnick LS, Creton D et al.: Duplex ultrasound scan findings two years after great saphenous vein radiofrequency endovenous obliteration. *J Vasc Surg* 2004; 39(1): 189-95.
42. Kianifard B, Holdstock JM, Whiteley MS: Radiofrequency ablation (VNUS closure) does not cause neo-vascularisation at the groin at one year: results of a case controlled study. *Surgeon* 2006; 4(2): 71-74.
43. Disselhoff BC, der Kinderen DJ, Kelder JC et al.: Five-year Results of a Randomised Clinical Trial of Endovenous Laser Ablation of the Great Saphenous Vein with and without Ligation of the Saphenofemoral Junction. *Eur J Vasc Endovasc Surg* 2011; 41(5): 685-90.
44. Theivacumar NS, Dellagrammaticas D, Beale RJ et al.: Fate and clinical significance of saphenofemoral junction tributaries following endovenous laser ablation of great saphenous vein. *Br J Surg* 2007; 94(6): 722-25.
45. Labropoulos N, Bhatti A, Leon L et al.: Neovascularization after great saphenous vein ablation. *Eur J Vasc Endovasc Surg* 2006; 31(2): 219-22.
46. Theivacumar NS, Gough MJ: Arterio-venous fistula following endovenous laser ablation for varicose veins. *Eur J Vasc Endovasc Surg* 2009; 38(2): 234-36.



47. *Timperman PE*: Arteriovenous fistula after endovenous laser treatment of the short saphenous vein. *J Vasc Interv Radiol* 2004; 15(6): 625-27.
48. *Allegra C, Antignani PL, Carlizza A*: Recurrent varicose veins following surgical treatment: our experience with five years follow-up. *Eur J Vasc Endovasc Surg* 2007; 33(6): 751-56.
49. *Jiang P, van Rij AM, Christie R* et al.: Recurrent varicose veins: patterns of reflux and clinical severity. *Cardiovasc Surg* 1999; 7(3): 332-39.
50. *Lurie F, Creton D, Eklof B* et al.: Prospective randomized study of endovenous radiofrequency obliteration (closure procedure) versus ligation and stripping in a selected patient population (EVOLVEs Study). *J Vasc Surg* 2003; 38(2): 207-14.
51. *Subramonia S, Lees T*: Randomized clinical trial of radiofrequency ablation or conventional high ligation and stripping for great saphenous varicose veins. *Br J Surg* 2010; 97(3): 328-36.
52. *Fernández CF, Roizental M, Carvalho J*: Combined endovenous laser therapy and microphlebectomy in the treatment of varicose veins: Efficacy and complications of a large single-center experience. *J Vasc Surg* 2008; 48(4): 947-52.
53. *Zimmet SE, Min RJ*: Temperature changes in perivenous tissue during endovenous laser treatment in a swine model. *J Vasc Interv Radiol* 2003; 14(7): 911-15.

Received: 18.11.2011 r.

Address correspondence: 61-848 Poznań, ul. Długa 1/2